



## International Journal of Gerontology

journal homepage: <http://www.sgecm.org.tw/ijge/>

## Case Report

## Sorafenib-Induced Radiation in-Field Skin (SIRIS) Reaction: Unexpected Complication in Elder Hepatocellular Carcinoma Patients Received Sorafenib and Concurrent Radiation Therapy

John Chun-Hao Chen<sup>a,b</sup>, Shih-Hua Liu<sup>b</sup>, Tsung-Yu Yen<sup>b</sup>, Kun-Yao Dai<sup>b</sup>,  
Jeng-Jong Hwang<sup>a\*\*</sup>, Yu-Jen Chen<sup>b\*</sup>

<sup>a</sup> Department of Biomedical Imaging and Radiological Sciences, National Yang-Ming University, Taipei, Taiwan, <sup>b</sup> Department of Radiation Oncology, Mackay Memorial Hospital, Taipei, Taiwan

## ARTICLE INFO

Accepted 9 March 2018

## Keywords

Hepatocellular carcinoma,  
Sorafenib,  
Radiation,  
Skin reaction

## SUMMARY

Sorafenib has been established as one of the standard treatment for unresectable hepatocellular carcinoma, but the prognosis for this disease remains poor. Therefore, other treatment modalities such as local radiation therapy were widely investigated in many trials. As a result, the combination of Sorafenib and radiation therapy offered some promising results, but the distinct adverse effects of targeted therapeutics combined with radiation therapy were also observed. An undefined and rarely-reported skin reaction was observed in 2 elder patients with advanced hepatocellular carcinoma who underwent concurrent Sorafenib and radiation therapy. We describe this phenomenon as Sorafenib induced radiation in-field skin (SIRIS) reaction, and the clinical course and radiation dosimetry of these patients were reviewed. The development of SIRIS reaction was primarily limited within the radiation treatment fields, and it occurred at a relatively low dose during the courses of RT. The SIRIS reaction progressed in a radiation dose-dependent manner and was recovered spontaneously after 3–4 weeks of radiation therapy. The SIRIS reaction implicates a unique phenomenon that systemic skin reaction of targeted therapeutics, such as sorafenib, might be limited or exacerbated in specific regions by local radiation therapy.

Copyright © 2019, Taiwan Society of Geriatric Emergency &amp; Critical Care Medicine.

## 1. Introduction

Hepatocellular carcinoma (HCC) is the third leading cause of cancer-related death in the world with more than 700,000 new cases diagnosed every year, although early detection by ultrasonography is feasible but the prognosis for advanced stages remain poor.<sup>1</sup> Common treatment options for unresectable HCC include ablation, chemoembolization, liver transplantation, radio-embolization and chemotherapy.<sup>2–6</sup>

There is growing evidence for the use of multikinase inhibitors such as Sorafenib, which have demonstrated survival benefits for selected patients.<sup>7</sup> In recent years, external beam radiation therapy has also emerged as a treatment option in advanced HCC, where conventional three-dimensional conformal treatment evolved to intensity-modulated radiation therapy (IMRT), stereotactic body radiation therapy (SBRT) and particle therapy.<sup>8</sup> Although randomized studies have not demonstrated the benefit of RT in HCC treatment, several prospective and retrospective studies have reported

favorable outcomes for HCC with portal vein tumor thrombosis.<sup>9</sup> For advanced HCC, benefits of combining radiation therapy and Sorafenib have also been reported.<sup>10</sup> However, severe adverse effects must be taken into consideration due to the potential radiosensitization of normal tissues by Sorafenib, such as bowel perforation.<sup>11</sup> In this report, we present a unique skin reaction observed in 2 elder HCC patients treated with external beam radiation therapy combined with sorafenib, where similar pattern was only reported in a renal cell carcinoma patient.<sup>12</sup> We describe this phenomenon as Sorafenib-induced radiation in-field skin (SIRIS) reaction, and there were several characteristics. First of all, the observed area of SIRIS reaction matches with the radiation treatment fields, and it also progressed in a radiation dose dependent manner. Secondly, the SIRIS reaction was noted at a relative low dose, which is uncommon when treating the liver with external beam radiation. Finally, this type of adverse effect was self-limited and these two patients recovered from SIRIS reaction after 3–4 weeks of radiation therapy.

## 2. Case report

The clinical history and external beam radiation dosimetry of 2 advanced HCC patients were retrospectively reviewed, they were 62 and 67 years old upon diagnosis. The linear accelerators used for external beam radiation therapy were Elekta Synergy (Elekta Ltd, Crawley, West Sussex, UK) and Tomotherapy Hi-art system

\* Corresponding author. Department of Radiation Oncology, Mackay Memorial Hospital, No. 92, Sec. 2, Zhongshan N. Rd, Taipei, 104, Taiwan.

\*\* Corresponding author. Department of Biomedical Imaging and Radiological Sciences, National Yang-Ming University, No. 155, Sec.2, Linong Street, Taipei, 112, Taiwan.

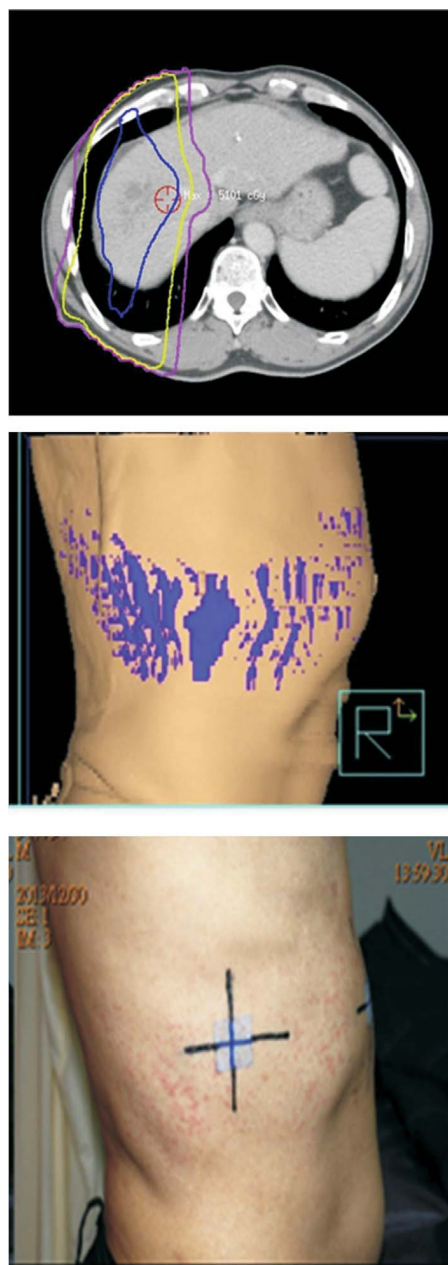
E-mail addresses: [jjhwang@ym.edu.tw](mailto:jjhwang@ym.edu.tw) (J.-J. Hwang), [chenmdphd@gmail.com](mailto:chenmdphd@gmail.com) (Y.-J. Chen).

(Tomotherapy Inc., Madison, WI, USA). The photon beam energy was 10 MV for Elekta Synergy, and the beam energy of Tomotherapy Hi-art system was 6 MV. The dose rates ranged from 400 to 600 MU. The modality of radiation therapy included ARC IMRT and Tomotherapy. The radiation treatment planning systems used were Pinnacle version 9.10 and Tomotherapy planning station version 4.2.3.

From 2014 to 2017, a unique pattern of skin reaction was observed in 2 male patients with locally advanced hepatocellular carcinoma who received concurrent Sorafenib and external beam radiation therapy during the courses of their treatments (Table 1). These elderly patients were all treated with first line treatment options such as surgery, transarterial embolization (TAE), transarterial chemoembolization (TACE), radiofrequency ablation (RFA) and percutaneous ethanol injection therapy (PEIT). Sorafenib and photon beam external beam radiation therapy were given because of disease progression. Both patients received RT (45–50.4 Gy with 1.8 Gy daily fraction) with a curative intent. The daily dosage of oral Sorafenib was 400 mg twice daily. During the courses of concurrent Sorafenib and radiation therapy, grade 1–2 SIRIS reaction occurred as early as the 10th day of radiation therapy in one of the patient, where the accumulated dose to the tumor site at the time was 18 Gy. Upon reviewing the radiation dosimetry, the SIRIS reaction site matched with the beam arrangement of the radiation treatment field despite the difference in RT modalities, and the prescribed dose to the tumor and lower dose distributions to the involved skin area were demonstrated (Fig. 1 and Fig. 2). The medical history of the patients showed these skin reactions increased in a radiation dose-dependent manner, where Sorafenib was held or given at a lower dose because drug related adverse effect was initially suspected. The blood counts and liver enzymes were within normal range in all patients during concurrent treatment of Sorafenib and RT. The SIRIS reaction recovered spontaneously after 3–4 weeks of RT for all patients. During the initial assessment after the treatment, partial response was observed in 1 patient (Fig. 3), the other patient is still under routine follow up with stable disease.

### 3. Discussion

Sorafenib is a multikinase inhibitor that targets Raf, vascular endothelial growth factor (VEGF) receptors and platelet-derived growth factor (PDGF) receptors, which affects tumor signaling and the tumor vasculature.<sup>13</sup> Although the use of sorafenib alone for advanced HCC had shown clinical benefits, the gain in survival remains modest.<sup>14</sup> Modern IMRT, SBRT and particle therapy allowed the escalation of the tumor dose while sparing the normal tissue.<sup>15</sup> In vitro and in vivo preclinical studies have suggested that Sorafenib may act as a radiosensitizer through suppression of the NF- $\kappa$ B pathway, and its combination with radiation therapy may enhance

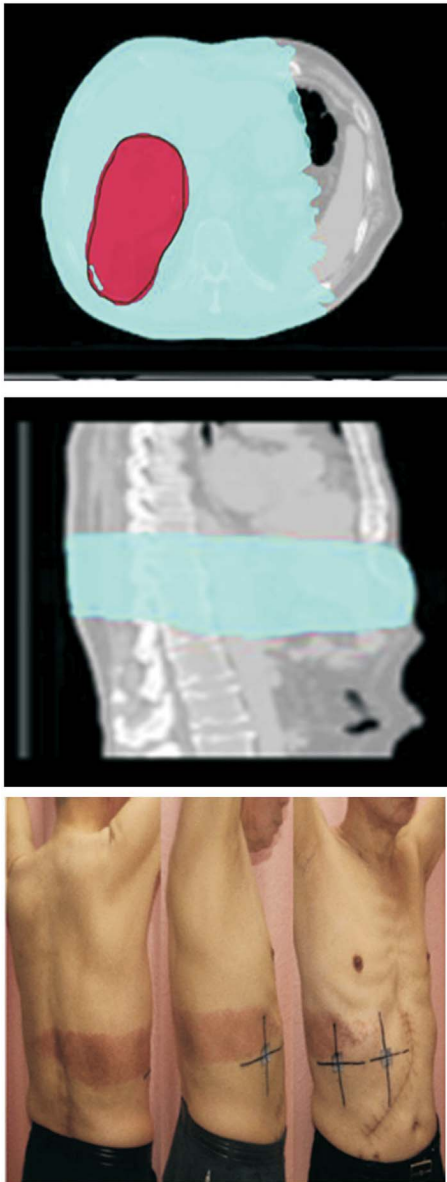


**Fig. 1.** From top to bottom: The radiation beam arrangements, different gradient of dose distributions and the SIRIS reaction for patient #1, dark blue area shows 45 Gy to tumor, yellow area shows 20 Gy and purple area shows 10 Gy.

**Table 1**  
The characteristics of patients.

Patients	#1	#2
Age	62	67
Gender	Male	Male
Stage	BCLC A	BCLC A
Initial treatment	TAE, RFA, PEIT	segmental hepatectomy, TACE
RT target	Recurrent tumor	Recurrent tumor
RT dose and fractionation	45 Gy/25 FX	50 Gy/28 FX
RT modality	ARC IMRT	Tomotherapy
Sorafenib dose	400 mg BID	400 mg BID
SIRIS onset	10th day of RT	16th day of RT
SIRIS recovery	Yes	Yes

tumor control.<sup>16,17</sup> As a result, clinical studies that combined Sorafenib and radiation therapy for HCC have been reported. A phase 2 study evaluated the efficacy of IMRT with concurrent sorafenib in patients with unresectable HCC,<sup>18</sup> the results demonstrated acceptable tolerability and tumor response was noted in 55% of the patients. The incidence of grade 3 toxicities was comparable with data from Sorafenib alone clinical trials, and the toxicities of sorafenib seemed not to be increased during the RT course. Another phase 1 clinical trial evaluated the combination of sorafenib and SBRT.<sup>19</sup> Tumor response rate ranged from 36 to 50% but significant gastrointestinal and hepatic toxicities were observed. As for the unique pattern of SIRIS reaction observed in our patients, this phenomenon was not specifically reported in these larger clinical trials.



**Fig. 2.** From top to bottom: the radiation beam arrangements, different gradient of dose distributions and the SIRIS reaction for patient #2, red area shows 50.4 Gy at tumor and blue area shows 10 Gy.

All our patients started their treatments with Sorafenib alone, but disease control was not achieved so radiation therapy was then added to the treatment. For one of our patients (patient #1), partial tumor shrinkage was demonstrated following concurrent treatment of Sorafenib and RT, this could be the result of sorafenib-enhanced intrinsic radiosensitivity of tumor cells.

The SIRIS reaction observed in our patients has several features. Our analysis showed the area of these skin lesions matched with the radiation treatment fields and the lower radiation dose distributions. As the radiation dose accumulated during the treatment, the severity of the SIRIS reaction seemed to progress in a radiation dose-dependent manner, and these skin reactions recovered after 3–4 weeks after radiation therapy for all patients. This unique adverse effect could be another indirect evidence of the enhanced radiosensitivity of Sorafenib. Our findings are also different from reports of radiation recall dermatitis, where an acute inflammatory reaction is confined to previously irradiated skin, mainly subsequent to the administration of Sorafenib. The SIRIS reaction might be related to the NF- $\kappa$ B pathway previously mentioned but requires more study, while some authors hypothesized that potential triggers of RRD might be impaired epithelial function induced by the radiation effect on epithelial stem cells, changes in vascularization, or DNA repair.<sup>20</sup> The severity of SIRIS reaction and RRD both seems to be radiation dose dependent. As of now, Sorafenib is considered as the standard therapeutic agent for advanced HCC. The recent technical advances also allow more HCC patients to receive different modalities of modern radiation therapy. Therefore, the development of SIRIS reaction in HCC patients may have important implications in the future, and the underlie mechanisms warrants more investigation.

**Funding**

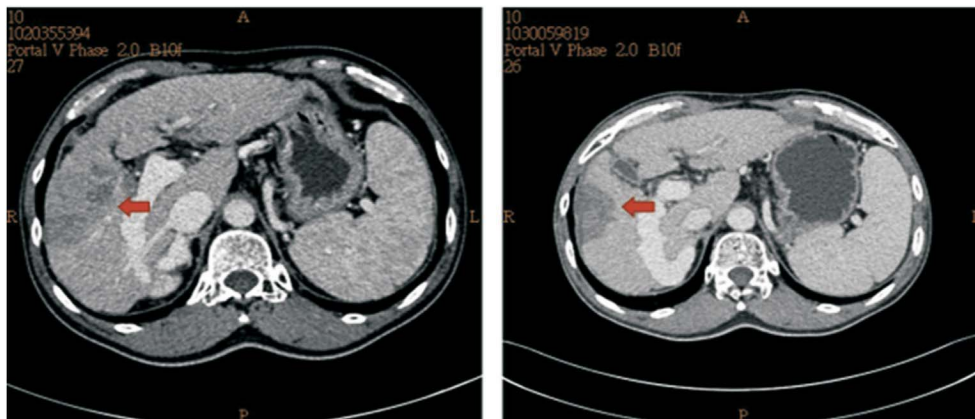
The author(s) received no financial support for the research, authorship, and/or publication of this article.

**Conflicts of interest**

The authors declare no conflicts of interest in preparing this article.

**References**

1. Forner A, Reig M, Bruix J. Hepatocellular carcinoma. *Lancet*. 2018 Jan 4.



**Fig. 3.** The treatment response for patient #1: the arrows indicate the tumor before IMRT and Sorafenib (left) and the tumor after treatment (right).

- [https://doi.org/10.1016/S0140-6736\(18\)30010-2](https://doi.org/10.1016/S0140-6736(18)30010-2). pii: S0140-6736(18)30010-2. [Epub ahead of print].
- Tiong L, Maddern GJ. Systematic review and meta-analysis of survival and disease recurrence after radiofrequency ablation for hepatocellular carcinoma. *Br J Surg*. 2011;98:1210–1224.
  - Llovet JM, Bruix J. Systematic review of randomized trials for unresectable hepatocellular carcinoma: chemoembolization improves survival. *Hepatology*. 2003;37:429–442.
  - Clavien PA, Lesurtel M, Bossuyt PM, et al. Recommendations for liver transplantation for hepatocellular carcinoma: an international consensus conference report. *Lancet Oncol*. 2012;13:e11–e22.
  - Kokabi N, Camacho JC, Xing M, et al. Open-label prospective study of the safety and efficacy of glass-based yttrium 90 radioembolization for infiltrative hepatocellular carcinoma with portal vein thrombosis. *Cancer*. 2015;121:2164–2174.
  - Kaseb AO, Shindoh J, Patt YZ, et al. Modified cisplatin/interferon alpha-2b/doxorubicin/5-fluorouracil (PIAF) chemotherapy in patients with no hepatitis or cirrhosis is associated with improved response rate, resectability, and survival of initially unresectable hepatocellular carcinoma. *Cancer*. 2013;119:3334–3342.
  - Llovet JM, Ricci S, Mazzaferro V, et al. Sorafenib in advanced hepatocellular carcinoma. *N Engl J Med*. 2008;359:378–390.
  - Hoffe SE, Finkelstein SE, Russell MS, et al. Nonsurgical options for hepatocellular carcinoma: evolving role of external beam radiotherapy. *Cancer Control*. 2010;17:100–110.
  - Yu JI, Park HC. Radiotherapy as valid modality for hepatocellular carcinoma with portal vein tumor thrombosis. *World J Gastroenterol*. 2016;22:6851–6863.
  - Horgan AM, Dawson LA, Swaminath A, et al. Sorafenib and radiation therapy for the treatment of advanced hepatocellular carcinoma. *J Gastrointest Cancer*. 2012;43:344–348.
  - Peters NA, Richel DJ, Verhoeff JJ, et al. Bowel perforation after radiotherapy in a patient receiving sorafenib. *J Clin Oncol*. 2008;26:2405–2406.
  - Diaz O, Mazon R, Martin E, et al. Toxicity of radiation therapy and antiangiogenics combination: a case report. *Cancer Radiother*. 2009;13:205–208.
  - Wilhelm S, Carter C, Lynch M, et al. Discovery and development of sorafenib: a multikinase inhibitor for treating cancer. *Nat Rev Drug Discov*. 2006;5:835–844.
  - Cheng AL, Kang YK, Chen Z, et al. Efficacy and safety of sorafenib in patients in the Asia-Pacific region with advanced hepatocellular carcinoma: a phase III randomised, double-blind, placebo-controlled trial. *Lancet Oncol*. 2009;10:25–34.
  - Park SH, Kim JC, Kang MK. Technical advances in external radiotherapy for hepatocellular carcinoma. *World J Gastroenterol*. 2016;22:7311–7321.
  - Chen JC, Chuang HY, Hsu FT, et al. Sorafenib pretreatment enhances radiotherapy through targeting MEK/ERK/NF-kappaB pathway in human hepatocellular carcinoma-bearing mouse model. *Oncotarget*. 2016;7:85450–85463.
  - Li Q, Hu Y, Xi M, et al. Sorafenib modulates the radio sensitivity of hepatocellular carcinoma cells in vitro in a schedule-dependent manner. *BMC Cancer*. 2012;12:485, 2012.
  - Chen SW, Lin LC, Kuo YC, et al. Phase 2 study of combined sorafenib and radiation therapy in patients with advanced hepatocellular carcinoma. *Int J Radiat Oncol Biol Phys*. 2014;88:1041–1047.
  - Brade AM, Ng S, Brierley J, et al. Phase 1 trial of sorafenib and stereotactic body radiation therapy for hepatocellular carcinoma. *Int J Radiat Oncol Biol Phys*. 2016;94:580–587.
  - Stieb S, Riesterer O, Brussow C, et al. Radiation recall dermatitis induced by sorafenib: a case study and review of the literature. *Strahlenther Onkol*. 2016;192:342–348.