



## International Journal of Gerontology

journal homepage: <http://www.sgecm.org.tw/ijge/>

## Original Article

## Conservative Management of Mechanical Small Intestinal Ileus in Geriatric Patients: A Retrospective Cohort Study of Decompression by Transnasal Ileus Tube

Weizhi Li, Di Li, Yu Wang, Lin Lang, Yu Wu \*

The Third Department of Gastrointestinal Surgery, Tianjin Hospital of Integrated Chinese and Western Medicine, Tianjin Nankai Hospital, Tianjin, China

## ARTICLE INFO

Accepted 26 August 2022

## Keywords:

tube feeding,  
ileus,  
small intestine,  
conservative treatment,  
therapeutic effect

## SUMMARY

**Objective:** To compare the therapeutic effects of transnasal ileus tubes (TNITs) and nasogastric tubes (NGTs) in elderly patients with mechanical ileus.**Methods:** The clinical data of 135 elderly patients (age > 65 years) with mechanical ileus were retrospectively analyzed from January 2017 to December 2020. They were divided into the TNITs group and the NGTs group according to their mode of conservative treatment. Post intervention symptomatic improvement, treatment safety, hospital stay, flatus time, defecation time, and eating time were compared between the two groups.**Results:** The tube retention time of the patients in the TNITs group was  $92.07 \pm 30.16$  h, shorter than that of the NGTs group ( $151.26 \pm 58.97$  h,  $p < 0.001$ ). The postoperative flatus time, defecation time, eating time and imaging efficacy in the TNITs group were shorter than those in the NGTs group (all  $p < 0.001$ ). The duration of hospital stay in the TNITs group was shorter than that in the NGTs group ( $7.98 \pm 2.79$  d vs.  $11.03 \pm 4.58$  d,  $p < 0.001$ ), and the drug costs were less than those in the NGTs group ( $26734.51 \pm 9836.43$  Chinese Yuan (CNY) vs.  $14965.63 \pm 5422.16$  CNY,  $p < 0.001$ ).**Conclusions:** Decompression by TNITs can quickly and effectively alleviate the symptoms of mechanical small bowel ileus in elderly individuals. It can also improve the success rate of conservative treatment and shorten the duration of hospital stay.

Copyright © 2023, Taiwan Society of Geriatric Emergency &amp; Critical Care Medicine.

## 1. Introduction

Mechanical ileus is a series of pathophysiological changes caused by various factors, and as a consequence, intestinal contents cannot pass through the intestinal cavity smoothly.<sup>1</sup> Mechanical ileus is one of the common diseases of the small intestine causing an acute clinical abdomen, leading to 300,000 or more admissions annually in the US, with an increasing prevalence during the last 30 years.<sup>2</sup> Patients with small bowel obstruction will experience frequent vomiting and fluid loss. This leads to electrolyte disorders, overgrowth of bacteria in the intestinal cavity, infections and the release of toxins, and also to the expansion of the intestinal canal, gas accumulation, effusion, and tissue damage to the intestinal wall.<sup>3,4</sup> Moreover, it can lead to intestinal necrosis, perforation, and even death when a blood supply disturbance occurs in the intestinal wall.<sup>2,5</sup>

Surgery is the main clinical treatment for patients with mechanical ileus, but some patients have a poor general condition and cannot tolerate surgical treatment.<sup>6,7</sup> Mechanical ileus of the small intestine is one of the common indications for abdominal surgery. However, elderly patients face a special challenge in that they have a high incidence of mechanical ileus. Adhikari Souvik et al.<sup>8</sup> reported

that the occurrence of acute intestinal obstruction in patients > 60 years was 26.7%. Elderly people tend to have poor physical fitness and poor tolerance of surgery because of comorbid conditions. Therefore, elderly patients have higher risks during surgical treatment. Decompression is a less-invasive, more conservative treatment for ileus.<sup>9</sup> Drainage of the effusion and gas from the gastrointestinal tract could relieve the symptoms of obstruction and restore intestinal function.<sup>10</sup>

In the conservative treatment of mechanical ileus, the insertion of transnasal ileus tubes (TNITs) guided by radiography has been widely used in recent years. However, the depth of tube placement, the decompression effect, and the safety of this treatment have not yet been thoroughly evaluated. Therefore, this study compared the efficacy of the placement of TNITs and nasogastric tubes (NGTs) guided by X-ray fluoroscopy for the treatment of mechanical ileus in geriatric patients.

## 2. Materials and methods

## 2.1. Study design

This was a retrospective cohort study. Clinical data from mechanical ileus patients treated from January 2017 to December 2020 at Tianjin Nankai Hospital, China were collected and analyzed. This study was conducted in accordance with the principles of the Decla-

\* Corresponding author. The Third Department of Gastrointestinal Surgery, Tianjin Hospital of Integrated Chinese and Western Medicine, Tianjin Nankai Hospital, No. 6, Chang Jiang Road, Nankai District, 300100, China.

E-mail address: [wuyu\\_tj@hotmail.com](mailto:wuyu_tj@hotmail.com) (Y. Wu)

ration of Helsinki and was approved by the Ethics Committee of Tianjin Nankai Hospital. All patients signed an informed consent form before treatment. Because this was a retrospective study, it was exempted from informed consent for inclusion in the study. A flow chart of this study can be found in Figure 1.

The minimum sample size was calculated by G power (Franz Faul, Germany). For a retrospective cohort study with a test level  $\alpha$  of 0.05 and a degree of assurance  $1-\beta$  of 0.9, the minimum size was 45 subjects for each group.

2.2. Inclusion and exclusion criteria

The inclusion criteria for the patients were as follows: (1) age > 65 years; (2) diagnosis of mechanical ileus; (3) clinical symptoms of intestinal obstruction, such as abdominal pain, vomiting, abdominal distension, and constipation; (4) diagnosis based on radiography (X-ray, computed tomography (CT)); and (5) no internal hernia, torsion, closed loop or other strangulation or dysvascularization.

The exclusion criteria were as follows: (1) condition complicated by gastrointestinal perforation and/or bleeding; (2) patients unwilling to undergo catheterization; (3) patients with severe heart disease, lung disease, or coagulation dysfunction; or (4) expected survival time less than 3 months.

A total of 135 patients were included, including 62 men and 73 women, with an average age of  $70.25 \pm 9.76$  years. All included patients were divided into two groups according to the type of tube placed, the TNITs group and the NGTs group. As this was a retrospective study, the selection of the tube type was made by the treating physician team after discussion.

2.3. Treatment

2.3.1. Treatment of the TNITs group

The patients were in the supine position. After nasopharynx anesthesia, the transnasal ileus tube (16DBR 3000T0, 16 Fr., length: 3000 mm, material: silicone, color: transparent, Dalian Create Medic, China) and the supporting supersliding guidewire were sent into

the gastric cavity through the nasal cavity. With the assistance of endoscopy, the TNITs was inserted into the jejunum through the pylorus and duodenum, and then the guidewire was withdrawn. Subsequently, 15 milliliters (ml) of water was filled into the anterior capsule, and the decompression interface at the tail end was connected to negative pressure drainage. Peristalsis of the intestinal tract could force the balloon-filled tube to slowly enter the deep part of the intestinal tract, and the external part of the tube was only stabilized, not fixed.

When the tube entry was blocked, 20 ml of air was injected into the posterior capsule, and the anterior capsule was evacuated. Iohexol was injected through the suction hole for X-ray radiography. After angiography, the negative pressure suction was turned off, and the iohexol was kept in the obstruction for 2 h; then, the negative pressure suction was turned on. At this time, the posterior capsule became a power capsule, pushing the anterior segment of the tube through the stenosis. The relief of the obstruction was evaluated by the imaging system. A schematic diagram of the placement process and images shown in Figure 2.

2.3.2. Treatment of the NGTs group

In the sitting or supine position, the nasogastric tube (SF \* GT1C16B, 16 Fr, length: 1250 mm, SAFEED™, TERUMO Corporation, Japan) was slowly inserted into the patient's nostril. When the tube reached the throat, the patient swallowed, and the tube passed from the esophagus to the stomach. The depth of the tube was approximately 45 cm. After placement, the tube was aspirated to confirm that it had entered the stomach. Finally, the tube was secured, and the depth was marked.

The qualifications of the operators in the two groups were the same. Patients in both groups received routine treatment for symptomatic support, such as correcting water-electrolyte disorder and acid-base imbalance, antibiotics, intravenous nutrition, fasting, and inhibiting gastrointestinal fluid secretion with somatostatin. If conversion to surgery became unavoidable, all patients were fully examined and evaluated, and the benefits and risks of the operation were explained in detail.

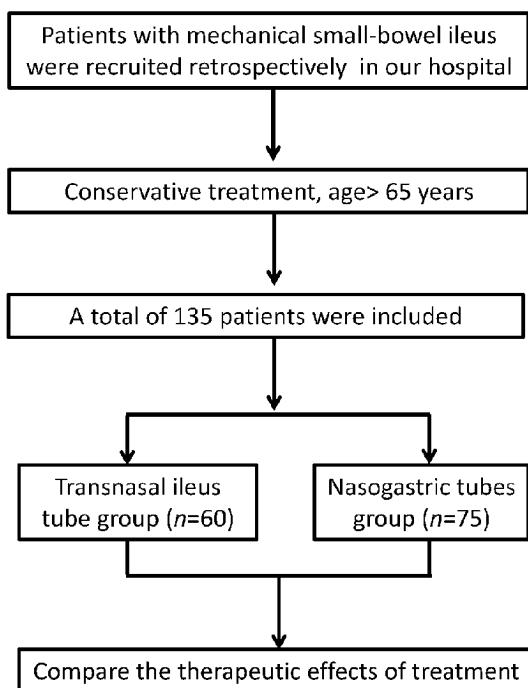


Figure 1. The flow chart of this study.

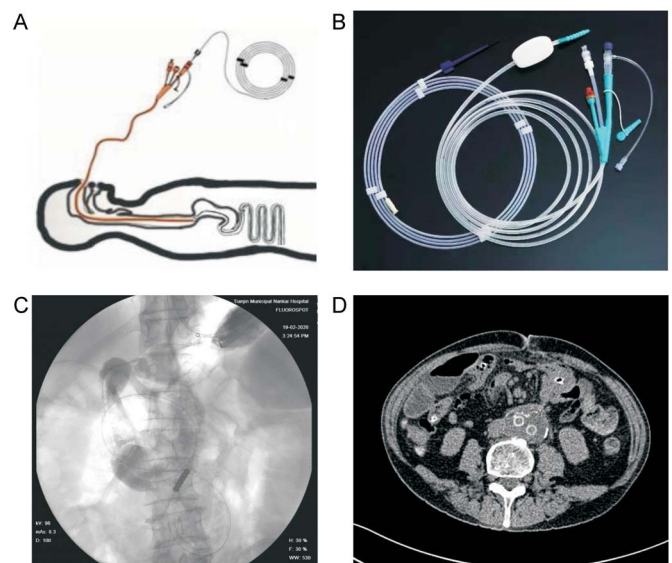


Figure 2. Decompression by a transnasal ileus tube in a 62-year-old man. A. Schematic diagram of the placement process; B. Images of the transnasal ileus tube; C. X-ray plain film after catheter placement; D. The CT after catheter decompression. The gas-liquid level in the abdomen disappears as the intestinal obstruction resolves.

## 2.4. Clinical data collection

### 2.4.1. Catheterization and efficacy

Based on the recorded information of the hospitalized patients, the depth and duration of tube placement were collected. The clinical efficacy of improving the small bowel obstruction, including the time elapsed between tube placement and passing flatus, passing stool, and taking the first bite of solid food, was also collected.

Imaging information was collected, including the time elapsed between tube placement and the disappearance of the gas-liquid level in the standing and lying positions on plain X-ray film, and the development time of the contrast agent in the colon by plain X-ray film in the standing and lying positions or by CT.

### 2.4.2. The efficacy criteria for the patients were as follows

(1) Significant effect: patients did not have clinical symptoms such as abdominal pain and abdominal distension after treatment, and their imaging characteristics returned to normal; (2) effective: the clinical symptoms were relieved, and the imaging characteristics improved; and (3) ineffective: the clinical symptoms and imaging characteristics of the patients did not improve significantly after treatment.

### 2.4.3. A safety evaluation was conducted for each treatment modality

The complications, including pharyngeal discomfort caused by catheterization, pneumonia during hospitalization, and intervention-related perforation, were compared between the two groups. The rate of conversion to surgery was also collected and compared.

### 2.4.4. An evaluation of hospitalization efficiency

Including total hospitalization time, hospitalization expenses, drug expenses, and proportion of drug expenses, was compared between the groups.

## 2.5. Statistical analysis

Statistical Product and Service Solutions software (25.0, Chicago, IL, USA) was used to analyze the data. Measurement data are expressed as the mean  $\pm$  SD, and Student's *t*-test was used for intergroup comparisons. Enumeration data were analyzed with the  $\chi^2$  test or Fisher probabilities.  $p < 0.05$  was considered statistically significant.

## 3. Results

### 3.1. Process and results of tube placement

Decompression for patients with mechanical ileus was performed in the interventional operating room by two trained general surgeons. There were no significant differences in the demographic data between the TNITs group and the NGTs group (all  $p > 0.05$ ), see Table 1.

The patients in the TNITs group had tubes placed successfully in the distal jejunum of the Treitz ligament, and the length of tube placement ranged from 180 to 230 cm. All had varying degrees of small intestinal fluid trans catheter reflux after successful placement, with an initial drainage volume of 1500 to 3000 ml.

In the NGTs group, all tubes were placed successfully in the stomach, and the placement length was 50~75 cm. The drainage volume on the first day was 300~1000 ml.

The tube retention time in the TNITs group was  $92.07 \pm 30.16$  h, which was shorter than in the NGTs group ( $151.26 \pm 58.97$  h) ( $p < 0.001$ ).

### 3.2. Comparison of therapeutic effects between the two groups

In the TNITs group, 54 cases were completely relieved after conservative treatment combined with tube placement, and 6 cases required surgery. The effective rate was 90%. In the NGTs group, 63 cases of mechanical ileus were completely relieved after the placement of the tube, and 12 cases required surgery. The effective rate was 84%. Although the effective rate in the TNITs group was higher, there was no significant difference between the two groups ( $\chi^2 = 1.038$ ,  $p = 0.308$ ).

The postoperative flatus time, defecation time, eating time, and imaging efficacy in the TNITs group were shorter than those in the NGTs group, and the differences were statistically significant (all  $p < 0.001$ ), as shown in Table 2.

### 3.3. Comparison of the safety of the two groups

After conservative treatment, 6 patients in the TNITs group underwent a conversion operation, including 2 cases of small intestinal adhesion lysis, 3 cases of partial resection of the small intestine (1

**Table 1**  
Comparison of general data between the two groups.

Variables	TNITs group (n = 60)	NGTs group (n = 75)	p-value
Age (years)	69.84 $\pm$ 9.61	70.28 $\pm$ 10.57	0.803
Gender			
Male, n (%)	25 (41.67)	37 (49.33)	0.374
Female	35 (58.33)	38 (60.67)	
BMI (kg/m <sup>2</sup> )	26.93 $\pm$ 5.02	27.51 $\pm$ 4.43	0.478
ASA classification			0.219
I	13 (21.67)	18 (24.00)	
II	30 (50.00)	45 (60.00)	
III	17 (28.33)	12 (16.00)	
History of abdominal surgery, n (%)			0.454
Open surgery	40 (66.67)	46 (61.33)	
Laparoscopic surgery	12 (20.00)	19 (25.33)	
Time from symptom to hospitalization (h)	3.97 $\pm$ 1.12	4.13 $\pm$ 1.35	0.462
Cause of ileus			0.365
Intestinal stone, n (%)	7 (11.67)	15 (20.00)	
Adhesive intestinal obstruction, n (%)	49 (81.67)	57 (76.00)	
Neoplastic intestinal obstruction, n (%)	4 (6.67)	3 (4.00)	

ASA, American Society of Anesthesiologists; GNTs, nasogastric tubes; TNITs, transnasal ileus tube.

**Table 2**  
Comparison of the decompression effect between the two groups (Mean  $\pm$  SD)

Variables	TNITs group (n = 60)	NGTs group (n = 75)	p-value
Tube depth (cm)	63.23 $\pm$ 9.28	209.14 $\pm$ 23.55	< 0.001
Retention time (h)	92.07 $\pm$ 30.16	151.26 $\pm$ 58.97	< 0.001
Postoperative exhaust (min)	56.38 $\pm$ 20.47	125.53 $\pm$ 43.72	< 0.001
Postoperative defecation (min)	68.41 $\pm$ 24.05	135.71 $\pm$ 42.36	< 0.001
Postoperative eating (min)	102.75 $\pm$ 37.60	181.46 $\pm$ 77.84	< 0.001
Radiography			
Gas-liquid level disappearance (min)	104.98 $\pm$ 40.24	176.28 $\pm$ 69.97	< 0.001
Development time of colonic contrast medium (min)	102.59 $\pm$ 33.57	171.69 $\pm$ 64.15	< 0.001

GNTs, nasogastric tubes; TNITs, transnasal ileus tube.

case related to small intestinal perforation) and 1 case of small intestinal short-circuit anastomosis. In the NGTs group, 12 patients were converted to surgery after ineffective conservative treatment, including 4 cases of enterolithotomy, 5 cases of small intestinal adhesion lysis, and 3 cases of partial resection of the small intestine.

Both groups had different degrees of nasopharyngeal discomfort or mild pain after catheterization. However, there was no additional damage to the pharyngeal mucosa, complications of abdominal pain, or gastrointestinal bleeding. In the TNITs group, one patient underwent partial resection of the small intestine due to perforation of the small intestine caused by repeated attempts of the guidewire to pass through the narrowed segment of the intestine.

### 3.4. Hospital stay and cost

The average duration of stay in the TNITs group was 7.98  $\pm$  2.79 d, and the total cost of hospitalization was 26734.51  $\pm$  9836.43 Chinese yuan (CNY), of which the cost of drugs was 8194.36  $\pm$  3435.28 CNY, accounting for 30.73%. The average duration of stay in the NGTs group was 11.03  $\pm$  4.58 d, and the total cost of hospitalization was 25173.24  $\pm$  9314.65 CNY, of which the cost of drugs was 14965.63  $\pm$  5422.16 CNY, accounting for 59.85%. There were significant differences in stay duration and drug cost between the two groups, all  $p$  < 0.05 (Table 3).

## 4. Discussion

The rapid development of intestinal ileus causes distension of the intestinal lumen, intestinal mucosal ischemia, and hypoxia in a short time, and it can progress to intestinal ischemia necrosis, perforation, and other complications. For elderly patients who cannot tolerate surgery, decompression is the main conservative treatment for various types of intestinal obstruction. In this study, we compared the differences in the impact of the two types of tubes used in patients with mechanical ileus.

Decompression is the most predominant conservative treatment modality for the treatment of small bowel obstruction due to various causes. The aim is to remove the accumulated gas, digestive

fluids, and food from the gastrointestinal tract, reduce the pressure in the gastrointestinal tract, and promote the resolution of edema and the restoration of blood circulation in the intestinal wall of the obstructed segment.<sup>11–13</sup> Thus, the ultimate objective is to promote the restoration of intestinal patency.<sup>14</sup> Therefore, effective gastrointestinal decompression is the key to achieving the desired therapeutic results. An NGTs to apply conventional gastrointestinal decompression is much shorter than a TNITs. The end of an NGTs can only be placed in the stomach. The effect of decompression for a proximal intestinal obstruction is poor.<sup>15–17</sup>

At the end of the 20th century, with the progress of technology, various intestinal decompression tubes were designed based on the traditional nasogastric tube, including different materials, types, lengths, and scopes.<sup>18,19</sup> An intestinal decompression tube can be placed directly in the dilated intestinal loop, quickly alleviating the symptoms of the obstruction and restoring blood circulation to the intestinal wall. Therefore, mortality and complications related to small intestinal obstruction have been significantly reduced. Lai H et al.<sup>20</sup> found that long intestinal tube placement could improve symptoms (abdominal pain, abdominal bloating, and vomiting) and improve the quality of life of patients with severe malignant bowel obstruction. Li L et al.<sup>21</sup> reached the same conclusion for patients with phytobezoar intestinal obstruction.

The insertion method used in this study was first introduced by Yamaguchi D et al. in 2018.<sup>22</sup> The TNITs has a longer length (3000 mm) than previous tubes. The cause of pharyngeal discomfort in this study may be related to an excessively long TNITs. This catheter consists of three lumens and two balloons (anterior and posterior). One of the important design features is that the anterior balloon contains barium sulfate and is shaped like a string of beads, which can be visualized by X-ray. At the same time, the material used to make this catheter is soft and it passes easily through the flexures of the intestinal lumen.<sup>22,23</sup>

Currently, few studies have compared the efficacy of TNITs and NGTs in the conservative treatment of small bowel obstruction, and some conclusions are inconsistent. According to previous research, intestinal decompression can effectively alleviate the clinical symptoms of adhesive intestinal obstruction in elderly patients, improve

**Table 3**  
Comparison of complications and hospitalization outcomes between the two groups.

Variables	TNITs group (n = 60)	NGTs group (n = 75)	p-value
Conversion to surgery, n (%)	6 (10.00)	11 (14.67)	0.417
Complication, n (%)			0.025
Pharyngeal discomfort	45 (75.00)	28 (37.33)	
Pneumonia	0 (0.00)	4 (5.33)	
Perforation	2 (3.33)	0 (0.00)	
Duration of stay (d)	7.98 $\pm$ 2.79	11.03 $\pm$ 4.58	< 0.001
Hospitalization expenses (CNY)	26734.51 $\pm$ 9836.43	25173.24 $\pm$ 9314.65	0.347
Drug cost (CNY)	8194.36 $\pm$ 3435.28	14965.63 $\pm$ 5422.16	< 0.001

CNY, Chinese Yuan; GNTs, nasogastric tubes; TNITs, transnasal ileus tube.

their recovery rate and reduce the conversion to surgery rate.<sup>24,25</sup> However, approximately 10% of patients with intestinal ileus cannot receive effective treatment and need to undergo external surgery to relieve the obstruction.<sup>26</sup>

The present study showed that intestinal decompression could alleviate symptoms in most patients, and the effective rate of decompression in the TNITs group was higher than that in the NGTs group. Because the patients in this study included mechanical ileus caused by many reasons, the success rate of conservative treatment was higher in both groups. Of course, after conservative treatment, there are always a few patients whose symptoms cannot be alleviated or recur, which may make it difficult to alleviate the obstruction due to abdominal adhesions. For such patients, treatment with TNITs may still reduce pressure on the obstructed intestinal lumen, improve the patient's general condition, and prepare them for surgery.<sup>27</sup> At the same time, a TNITs can also be placed intraoperatively at the ileocaecal site as an internal stent.<sup>28</sup> Therefore, a TNITs is convenient and effective for the treatment of mechanical ileus and has good therapeutic value in both nonsurgical and surgical treatment.

The tube placement method can be assisted by radiography or endoscopy.<sup>29</sup> Tube placement under radiography guidance can directly reach the small intestine or even a lower obstruction site, and the success rate of tube placement can reach 90%~100%. The proximal intestinal wall of an intestinal obstruction is thin and edematous and prone to perforation. The perforation rate in the TNITs group in this study was higher. All perforations in patients in the TNITs group occurred in the small intestine and occurred early in the series due to unskilled operators. Then, with the increasing proficiency of the operator, perforations stopped occurring.

Our results showed that there were no significant differences in total hospitalization cost between the NGTs group and the TNITs group. However, the TNITs group had a shorter hospitalization time (or length of stay) and lower drug costs. This suggests that this technique can significantly improve hospitalization efficiency for the treatment of mechanical ileus. Because elderly patients can get out of bed early after a swift decompression by a TNITs, the incidence of pneumonia was significantly lower than in the NGTs group. Therefore, TNITs insertion is highly effective and safe during the nonsurgical treatment of mechanical ileus.

The present study also has the following shortcomings: (1) Because this study did not follow up the patients, the differences between the groups for long-term outcomes were not investigated. (2) The included patients did not have an absolute indication for surgery and had many different causes of ileus, so a detailed stratification analysis was not performed in the present study. The placement of the TNITs was nondirectly visible under X-ray. (3) Since the bowel wall at the proximal obstruction is often thin and congested, the placement of a TNITs can increase the risk of developing complications such as gastrointestinal perforation and bleeding. Therefore, improving the tube placement method may be an important way to improve the effect of conservative treatment in patients with mechanical small-bowel ileus.

In conclusion, intestinal decompression is the most commonly used conservative treatment for mechanical small-bowel ileus. TNITs placement can effectively improve obstruction symptoms, shorten the hospitalization time of older adults, and is superior to NGTs.

### Declaration of conflicting interests

All authors declare that they have no conflicts of interest in this study.

### Ethics approval and consent to participate

This study obtained permission from the Ethics Committee of Tianjin Nankai Hospital (Ethics number: NKYY\_YXKT\_IRB\_2019\_004\_01).

### Data access statement

All data generated and used are presented in this article.

### Funding

Not applicable.

### Acknowledgments

Not applicable.

### Consent for publication

Not applicable.

### Author contributions

All authors contributed significantly to this study. Li Weizhi and Wu Yu designed the trial. Li Di, Wang Yu, Lang Lin, and Li Weizhi have conducted the work and were involved in data collection. Li Di, Wang Yu, and Li Weizhi analyzed the data. Lang Lin, Li Weizhi, and Wu Yu interpreted the data. Li Weizhi and Wu Yu wrote the manuscript. All authors revised the manuscript.

### References

1. Rami Reddy SR, Cappell MS. A systematic review of the clinical presentation, diagnosis, and treatment of small bowel obstruction. *Curr Gastroenterol Rep.* 2017;19:28.
2. Cappell MS, Batke M. Mechanical obstruction of the small bowel and colon. *Med Clin North Am.* 2008;92:575–597.
3. Lin YM, Fu Y, Winston J, et al. Pathogenesis of abdominal pain in bowel obstruction: Role of mechanical stress-induced upregulation of nerve growth factor in gut smooth muscle cells. *Pain.* 2017;158:583–592.
4. Jackson P, Vigiola Cruz M. Intestinal obstruction: Evaluation and management. *Am Fam Physician.* 2018;98:362–367.
5. van Beekum CJ, Stoffels B, von Websky M, et al. Mechanical bowel obstruction in geriatric patients: Etiology and perioperative morbidity/mortality compared with a younger cohort. Article in German. *Med Klin Intensivmed Notfmed.* 2020;115:22–28.
6. Vilz TO, Stoffels B, Strassburg C, Schild HH, Kalff JC. Ileus in adults. *Dtsch Arztebl Int.* 2017;114:508–518.
7. Bower KL, Lollar DI, Williams SL, Adkins FC, Luyimbazi DT, Bower CE. Small bowel obstruction. *Surg Clin North Am.* 2018;98:945–971.
8. Adhikari S, Hossein MZ, Das A, Mitra N, Ray U. Etiology and outcome of acute intestinal obstruction: A review of 367 patients in eastern india. *Saudi J Gastroenterol.* 2010;16:285–287.
9. Li de C, Li RH, Tian Q. Efficacy of intestinal decompression with long nasointestinal tube and selective contrast radiography in the treatment of small bowel obstruction in elderly patients. *Minerva Chir.* 2016;71:85–90.
10. Li D, Li R, Wu P, Li X, Zhang X. Clinical and diagnostic significance of enteroclysis through nasointestinal decompression intubation. *Cell Biochem Biophys.* 2014;70:349–353.
11. Xu X, Cai L, Tian W, Yao Z, Zhao R, Zhao Y. Effects of different preoperative enteral nutrition feeding routes on the duration of gastrointestinal decompression after definitive surgery for small intestinal fistula. *Langenbecks Arch Surg.* 2021;406:2837–2848.
12. Chusilp S, Yamoto M, Vejchapipat P, Ganji N, Pierro A. Nasogastric decompression after intestinal surgery in children: A systematic review and

- meta-analysis. *Pediatr Surg Int.* 2021;37:377–388.
13. Rao W, Zhang X, Zhang J, Yan R, Hu Z, Wang Q. The role of nasogastric tube in decompression after elective colon and rectum surgery: A meta-analysis. *Int J Colorectal Dis.* 2011;26:423–429.
  14. Flick KF, Soufi M, Yip-Schneider MT, et al. Routine gastric decompression after pancreatoduodenectomy: Treating the surgeon? *J Gastrointest Surg.* 2021;25:2902–2907.
  15. Kumar Sinha A, Ahmad S, Rashi R, Kumar A, Kumar B. Self-knotting of distal end of nasogastric tube-not an uncommon possibility. *Pediatr Investig.* 2020; 4:145–147.
  16. Venara A, Hamel JF, Cotte E, et al. Intraoperative nasogastric tube during colorectal surgery may not be mandatory: A propensity score analysis of a prospective database. *Surg Endosc.* 2020;34:5583–5592.
  17. O'Connell F, Ong J, Donelan C, Pourmand A. Emergency department approach to gastric tube complications and review of the literature. *Am J Emerg Med.* 2021;39:259.e5–259.e7.
  18. Guo SB, Duan ZJ. Decompression of the small bowel by endoscopic long-tube placement. *World J Gastroenterol.* 2012;18:1822–1826.
  19. Luo Y, Zhu CK, Wu DQ, Zhou LB, Wang CS. Effect comparison of three different types of transanal drainage tubes after anterior resection for rectal cancer. *BMC Surg.* 2020;20:166.
  20. Lai H, Wu K, Liu Y, Zeng Z, Zhang B. Fluoroscopy-guided long intestinal tube placement for the treatment of malignant bowel obstruction. *Oncol Lett.* 2019; 17:5154–5158.
  21. Li L, Xue B, Zhao Q, Xie HQ, Luan XR, Cui Q. Observation on the curative effect of long intestinal tube in the treatment of phytobezoar intestinal obstruction. *Medicine (Baltimore).* 2019;98:e14861.
  22. Yamaguchi D, Morisaki T, Tsunada S. Effective insertion method of transnasal ileus tube for adhesive small bowel obstruction. *Dig Endosc.* 2018; 30:120–121.
  23. Yamaguchi D, Ikeda K, Takeuchi Y, et al. New insertion method of transnasal ileus tube for small bowel obstruction: Anterior balloon method. *PLoS One.* 2018;13:e0207099.
  24. Jakubauskas M, Luksaite R, Sileikis A, Strupas K, Poskus T. Gallstone ileus: Management and clinical outcomes. *Medicina (Kaunas).* 2019;55:598.
  25. Han XJ, Zhao F, Su HY, Xu K. Outcome of decompression using a transnasal ileus tube in malignant adhesive bowel obstruction: A retrospective study. *Mol Clin Oncol.* 2017;7:701–705.
  26. Li RH, Li DC, Lv XP, Quan B. Radiophotographically controlled nasointestinal intubation to treat recurrent postoperative adhesive ileus. *Cell Biochem Biophys.* 2015;72:509–514.
  27. Götz M, Braun G, Jakobs R, et al. German Society of Gastroenterology, Digestive and Metabolic Diseases (DGVS) position statement on endoscopic decompression in acute ileus. Article in German. *Z Gastroenterol.* 2017;55:1499–1508.
  28. Hosono M, Matsuda T, Yamashita K, et al. Successful single-stage laparoscopic surgery using a preoperative self-expanding metallic stent in patients with obstructive colorectal cancer. *Asian J Endosc Surg.* 2019;12: 401–407.
  29. Milsom SA, Sweeting JA, Sheahan H, Haemmerle E, Windsor JA. Nasoenteric tube placement: A review of methods to confirm tip location, global applicability and requirements. *World J Surg.* 2015;39:2243–2252.